

Concise Review With Video Illustration

Labral Base Refixation in the Hip: Rationale and Technique for an Anatomic Approach to Labral Repair

Robert Fry, M.D., and Benjamin Domb, M.D.

Abstract: Recent literature has defined the importance of anatomic repair in shoulder and knee arthroscopy. New advances in hip arthroscopy have created opportunities to apply the principle of anatomic repair to the hip. To address the obstacles in the restoration of labral anatomy, we describe an anatomic approach to labral refixation. We reviewed the literature on biomechanics of the labrum to identify the factors that are essential to the function of the labrum. Existing techniques for arthroscopic labral repair and potential challenges in restoration of labral anatomy were reviewed. A list of criteria for anatomic labral repair was created, and a technique for anatomic labral base refixation was developed. The technique incorporates the understanding of the function and biomechanical role of the labrum and builds on existing techniques to fulfill the criteria for restoration of anatomy. Our purpose was to review the anatomy, biomechanics, and existing repair techniques of the labrum, as well as to describe the rationale and surgical steps for anatomic labral base refixation in the hip.

Restoration of anatomy has become increasingly recognized as an essential principle of successful arthroscopic surgery. The trend toward restoration of anatomy has guided the development of techniques for anatomic repairs in the knee and shoulder, such as transosseous equivalent rotator cuff repair and anterior cruciate ligament footprint reconstruction.¹⁻⁹ With the recent advances in our understanding of hip arthroscopy and technologic advances, new opportunities are arising to apply the principle of anatomic repair to the hip.

From the Department of Orthopedics, Loyola University Medical Center, Maywood, Illinois, U.S.A.

B.D. received support from Arthrex, Naples, FL, exceeding the equivalent of US \$500 related to this research.

Received December 8, 2009; accepted January 21, 2010.

Address correspondence and reprint requests to Robert Fry, M.D., Department of Orthopedics, Loyola University Medical Center, 2160 S First Ave, Maguire Center, Ste 1700, Maywood, IL 60153, U.S.A. E-mail: robfry30@gmail.com

*© 2010 by the Arthroscopy Association of North America
0749-8063/9719/\$36.00*

doi:10.1016/j.arthro.2010.01.021

Note: To access the video accompanying this report, visit the September supplement issue of *Arthroscopy* at www.arthroscopyjournal.org.

RATIONALE FOR ANATOMIC LABRAL REPAIR

The importance of restoration of anatomic footprints in the shoulder and knee has been highlighted in *Arthroscopy*.¹⁰ Carrying this principle into the hip, it has been suggested that arthroscopic treatment of femoroacetabular impingement (FAI) should also aim to restore normal anatomy.¹¹ Labral tears in FAI occur as a result of cam, pincer, or combined impingement.¹² Correction of bony impingement may require osteoplasty of the cam lesion or acetabuloplasty of the pincer lesion. To perform acetabuloplasty while preserving the labrum, it is often necessary to detach the labrum before rim trimming. This technique requires subsequent arthroscopic refixation of the labrum so as to restore its native anatomy. It is theorized that such restoration of anatomy and resolution of impingement may prevent degeneration of the joint.¹²

According to a 2008 meta-analysis, open surgical dislocation for treatment of FAI and associated labral tears yields good to excellent results in 65% to 90% of patients (mean follow-up, 40 months) versus good to excellent results in 67% to 93% after arthroscopic

management of FAI (mean follow-up, 2 years).¹³ At 10 years' follow-up, Byrd and Jones¹⁴ reported successful outcomes in 82% of patients without arthritis at the time of arthroscopic labral debridement. Despite positive results with labral debridement and resection, elucidation of labral biomechanics has shifted emphasis to labral preservation. Preservation of the labrum may necessitate labral refixation, particularly when the labrum is detached for the acetabuloplasty. Espinosa et al.¹⁵ reported improved clinical outcomes with labral refixation versus resection with acetabuloplasty for FAI. More recently, favorable results have been reported with arthroscopic labral repair and treatment of FAI.¹⁶⁻²⁰

The labrum is thought to be important in multiple aspects of the biomechanics of the hip, including regulation of flow of synovial fluid, maintenance of the suction seal, stability, and load bearing.²¹⁻²⁵ Biomechanical studies have suggested that a functional labrum slows cartilage consolidation through its hydrostatic effects and therefore may serve a protective role for the articular cartilage.²⁴ Regulation of fluid flow and maintenance of the suction seal can only occur when femoral head contact is preserved in all parts of the labrum. The importance of the contact fit between the femoral head and labrum was emphasized by Ferguson et al.²⁴ When using arthroscopic techniques for labral refixation, surgeons are faced with the challenge of restoring the native anatomy of the labrum, as well as its contact with the femoral head, to successfully re-create its functionality.

CURRENT LABRAL REPAIR TECHNIQUES

Labral repair techniques have been described in the literature using suture anchors, screw anchors, and extra-articular sutures.²⁶⁻³⁰ The anchors are placed as close as possible to the acetabular rim without penetrating the articular surface. A cadaveric study defined a safe zone for anchor insertion of 2.3 to 2.6 mm from the rim with an anchor angle of 10°.³¹ When one is assessing the labrum for repair, the degenerative tissue must first be debrided. Recent repair descriptions emphasize preserving as much healthy labral tissue as possible to maintain anatomic function.²⁶ Although open labral refixation as described by Ganz³² generally involved passage of sutures through the labrum, most arthroscopic labral repair techniques previously described in the literature use simple stitches looped around the labrum (Fig 1).^{11,27,29}

There are several specific obstacles to restoration of labral function. Although the looped simple stitch

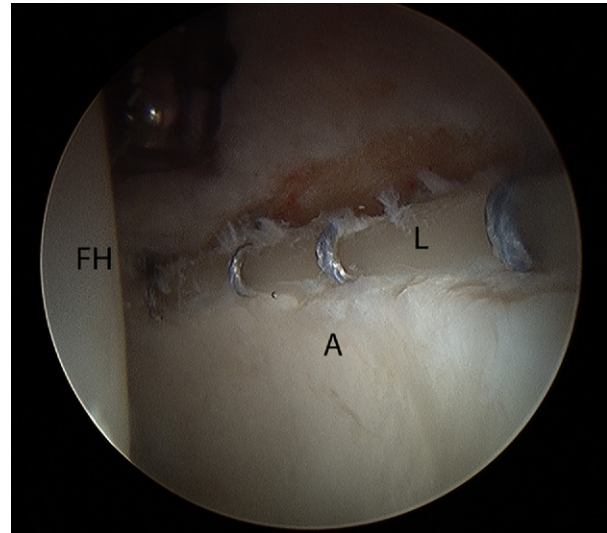


FIGURE 1. Arthroscopic labral repair with simple looped suture technique of left hip viewed from anterolateral portal in supine position. Although the repair achieves approximation of the labrum (L) to the acetabular rim (A), it is bunched into a cylindrical shape, failing to reproduce the native triangular cross-sectional shape. (FH, femoral head.)

technique can achieve fixation of the labrum to the acetabular rim, the labrum may be bunched and its normal triangular cross-sectional anatomy may be distorted (Fig 2A). The labrum may also be everted away from the femoral head, and thus the contact of the labrum with the femoral head may not be reproduced (Fig 3).²⁴ To address these problems, labral repair with vertical mattress sutures has also been reported.^{26,28,30} However, it has been suggested that puncturing the labrum with a penetrating instrument should be avoided because this may split or tear the labrum and possibly compromise the suction seal (Fig 4).²⁶ The modes by which labral repair may fail to restore full contact with the femoral head are summarized in Table 1.

SURGICAL TECHNIQUE: LABRAL BASE REFIXATION

Through consideration of the anatomic features of the labrum and its biomechanical significance, we identified 6 major goals of labral repair (Table 2). A surgical technique for arthroscopic labral base refixation (LBR) was developed to meet these 6 goals. The LBR technique incorporates previous outstanding landmark work that has defined the native anatomy and biomechanical importance of the labrum, as well as the clinical implications of labral preser-

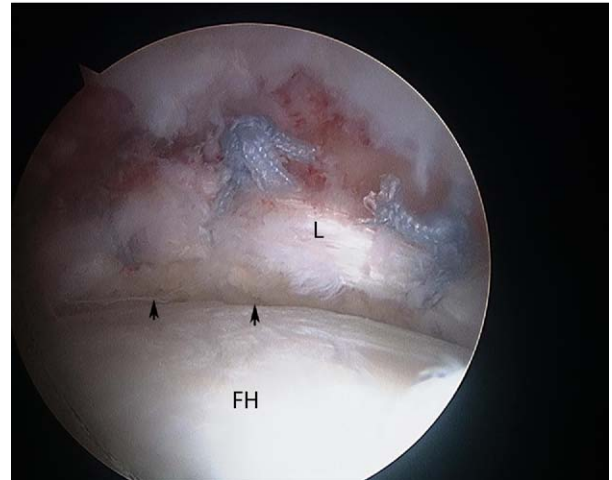
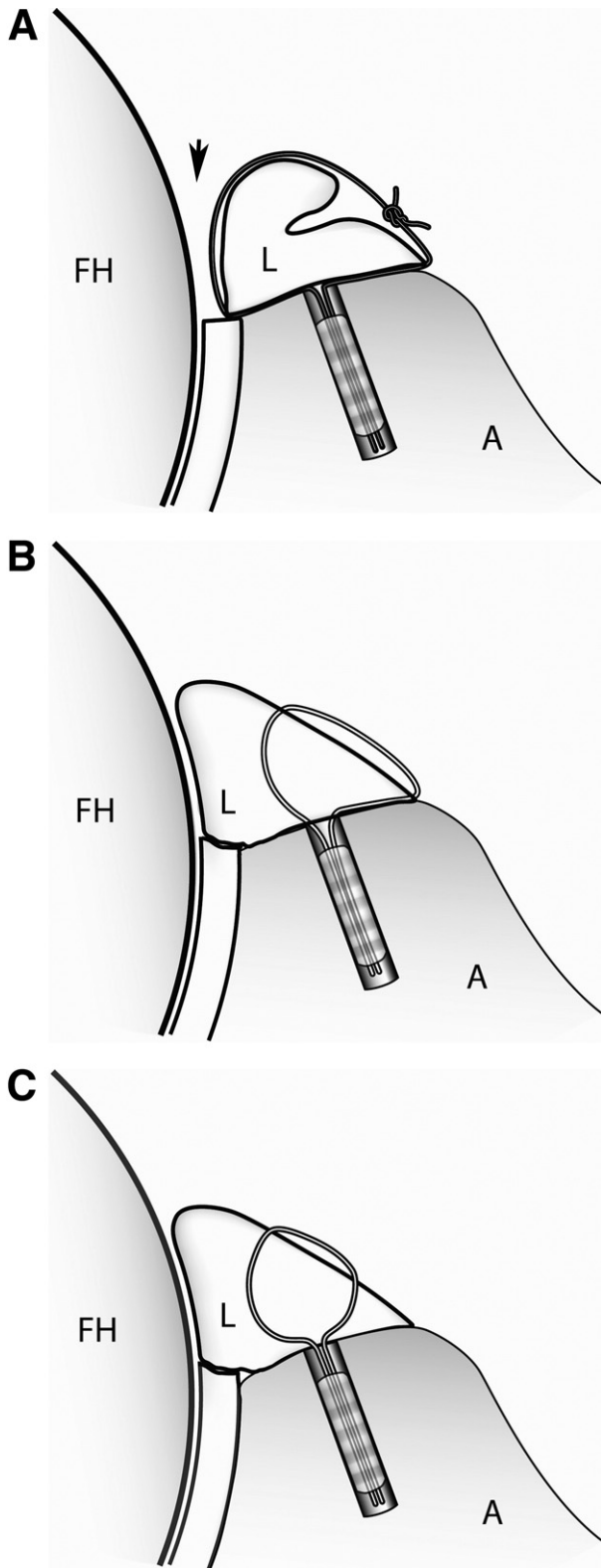


FIGURE 3. Labral repair with a simple stitch looped over the labrum in a left hip viewed from the anterolateral portal from the peripheral compartment. It should be noted that the repair achieves approximation of the labrum (L) to the acetabular rim but bunches the labrum and disrupts the contact seal (arrows) with the femoral head (FH). This figure also shows the first 3 modes of failure of nonanatomic simple stitch repair.

vation.^{13,15,26,28,33-36} To achieve restoration of the functional anatomy of the labrum, the procedure builds on the pioneering advances in technique by other authors who have made arthroscopic labral repair technically feasible.^{15,26,27,29,33,37} The purpose of this article is to describe the biomechanical rationale and critical steps for successful use of the LBR technique.

FIGURE 2. (A) Labral repair with a simple looped stitch that passes over the free edge of the labrum (L), causing bunching of the labrum and distortion of the normal triangular cross-sectional anatomy of the labrum. The labrum is bunched and everted away from the femoral head (FH), disrupting the contact seal (arrow). The first 3 modes of failure of nonanatomic labral refixation are illustrated here. (A, acetabulum.) (B) In LBR the labral base stitch involves a single passage of suture through the base of the labrum (L). This achieves secure fixation of the labral base while preserving the triangular cross-sectional anatomy of the labrum. The contact of the labrum with the femoral head (FH) is preserved, allowing the labrum to serve its function as a suction seal and in regulating fluid ingress and egress from the joint. (A, acetabulum.) (C) LBR with vertical mattress technique. The vertical mattress labral base stitch involves 2 passes of the suture through the base of the labrum (L). This technique is recommended when the width of the labrum is at least 5 mm. In addition to providing secure fixation of the labral base, this technique is ideal in preserving the triangular shape of the labrum and its fit against the femoral head (FH). (A, acetabulum.)

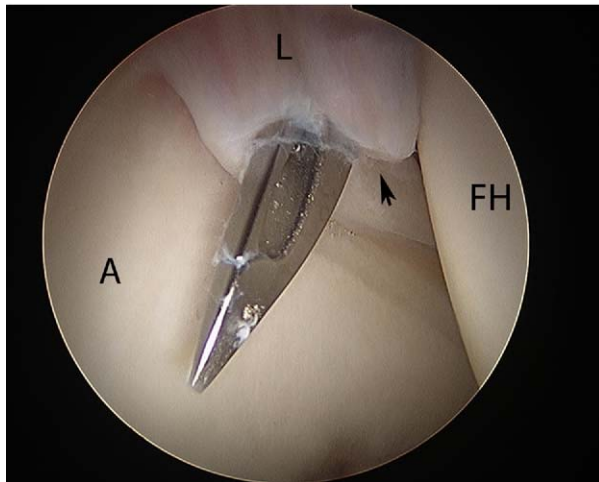


FIGURE 4. Splitting or intrasubstance tearing of the labrum (L) by a penetrating instrument in a right hip viewed from the anterolateral portal. The use of a larger penetrating instrument, as shown here, is likely to cause injury to the labrum by virtue of its larger diameter. To avoid such injury, a smaller-diameter penetrating device is preferred. (FH, femoral head; A, acetabulum.)

Portal Placement

The 2 portals that are routinely used are the anterolateral and midanterior portals, as described by Kelly et al.²⁶ These portals allow access to the majority of the acetabular rim and labrum, enabling treatment of the areas of common labral pathology and pincer impingement. These 2 portals also provide optimal angles for anchor placement on the acetabular rim between 12 and 5 o'clock in the anterosuperior and anteroinferior quadrants. When rim trimming and labral detachment are carried out in the posterosuperior quadrant, a posterolateral portal as described by Byrd³⁸ is used for rim trimming and anchor placement.

Acetabuloplasty With Labral Preservation

The LBR technique involves anatomic refixation of the labrum in cases of labral tears, usually in the setting of FAI. In its early stages, FAI may cause

TABLE 1. Modes by Which Nonanatomic Repairs May Fail to Restore Contact Seal of Labrum Around Femoral Head

Bunching of labrum due to compression by looped stitch (Fig 2A)
Distortion of triangular cross-sectional anatomy (Fig 2A)
Eversion of labrum away from femoral head (Fig 2A)
Splitting or intrasubstance tearing of labrum by penetrating instrument (Fig 3)

TABLE 2. Technique Goals in LBR

Avoid splitting or intrasubstance tearing of labrum
Securely reattach base of labrum to acetabular rim
Restore continuity of transitional zone between labrum and adjacent cartilage
Re-create triangular cross-sectional geometry of labrum
Restore suction seal by achieving contact between labrum and femoral head
Use knotless suture technique to avoid potential articular abrasion

tearing at the chondrolabral junction due to shear forces while sparing the tip of the labrum.³⁹ In these cases the degenerative base can be debrided and reattached, leaving the free edge to provide contact with the femoral head. However, labral refixation is most commonly applicable in FAI surgery involving acetabular rim trimming, or acetabuloplasty.

When the labrum is in adequate condition, it should be preserved during acetabuloplasty for subsequent refixation. Labral preservation during acetabuloplasty can be achieved in 2 ways:

1. For minimal trimming of the rim of less than 3 mm, acetabuloplasty without labral detachment may be performed. The capsule is elevated off of the acetabular rim in the area of pincer impingement by use of electrocautery, and a high-speed 5.5-mm bur is used to trim the acetabular rim on the capsular side of the labrum.
2. For trimming of more than 3 mm of rim, acetabuloplasty with labral detachment is generally performed. First, a minimal acetabuloplasty is performed on the capsular side, with resection of the first 3 mm of bone from the acetabular rim. This enables improved access for subsequent labral detachment with a beaver blade or tissue elevator, with preservation of a maximal amount of labral tissue (Fig 5). After completion of the labral detachment, the labrum is retracted away from the rim by use of the arthroscope or a switching stick while the remainder of the acetabuloplasty is performed.

When the labrum is unstable after acetabuloplasty, labral refixation is indicated. Notably, the acetabuloplasty creates a bleeding bed of bone to facilitate biological healing of the labrum to the acetabular rim after labral refixation. A decision algorithm for labral preservation and refixation during acetabuloplasty is shown in Fig 6.

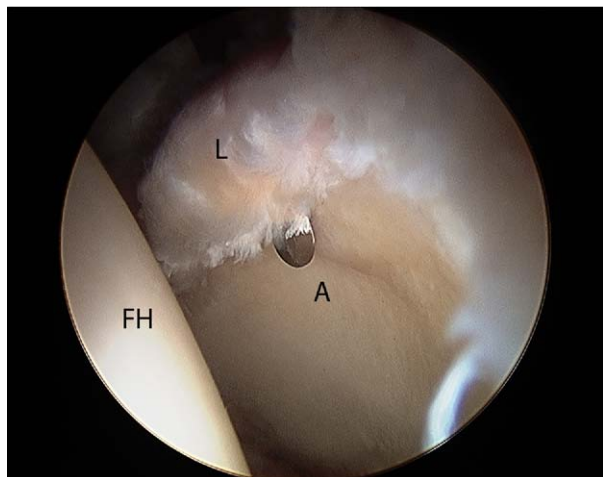


FIGURE 5. Labral detachment during acetabuloplasty of a left hip viewed from the anterolateral portal in the central compartment. Labral detachment is performed before acetabuloplasty so as to preserve the labrum (L) during the rim trimming. The beaver blade is used to carefully elevate the labrum off of the acetabular rim (A), with preservation of as much labral tissue as possible. The beaver blade is seen here cutting along the chondrolabral junction. The labrum can then be retracted away from the pincer lesion as acetabuloplasty is performed. (FH, femoral head.)

Suture Passage and Anchor Placement

The LBR technique makes use of a labral base stitch, which is passed by use of a Suture Lasso (Arthrex, Naples, FL) to pierce the labrum, and a stiff nonabsorbable suture is passed through its base (Fig 7). The narrow diameter of this instrument avoids splitting or intrasubstance tearing of the labrum, 1 of the potential pitfalls of puncture of the labrum. The angle of passage of this stitch is of vital importance in correctly restoring the labral anatomy. A knotless 2.9-mm PushLock suture anchor (Arthrex) is used to fix the suture to the acetabular rim (Fig 2B and Video 1 [available at www.arthroscopyjournal.org]). When the detached labrum is greater than 5 mm in thickness, the LBR is performed with a vertical mattress stitch technique by passing the suture twice through the labral base to achieve optimal anatomic refixation (Fig 2C). When the labrum is less than 3 mm in thickness, the LBR technique is not recommended because the thin labrum may not support the labral base stitch (Table 3).

The anchors may be placed through the posterolateral portal for the posterosuperior quadrant, the anterolateral portal for the anterosuperior quadrant between 12 and 2 o'clock, or the midanterior portal between 2 and 5 o'clock for the anterosuperior and

anteroinferior quadrants (Table 4). These clock-face guidelines reflect a right hip in the supine position, where 12 o'clock is superolateral, 3 o'clock is directly anterior, 6 o'clock is inferior at the transverse acetabular ligament, and 9 o'clock is directly posterior. This procedure is repeated for as many anchors as necessary to achieve appropriate fixation of the entire detached portion of the labrum. Anchors are normally spaced 6 to 8 mm apart. The LBR technique re-creates the triangular cross-sectional shape of the labrum and avoids eversion of the labrum away from the joint. When viewed from the articular side, the transitional zone between the labrum and acetabular cartilage is well restored (Fig 8A). After traction is released, the view from the peripheral compartment confirms contact between all parts of the labrum and the femoral head, allowing restoration of labral function (Fig 8B).

DISCUSSION

The acetabular labrum is a peripheral articular fibrocartilage complex that adds depth to joint geometry and increases articular contact.²¹ The labrum has been shown to increase articulating surface by 22% and

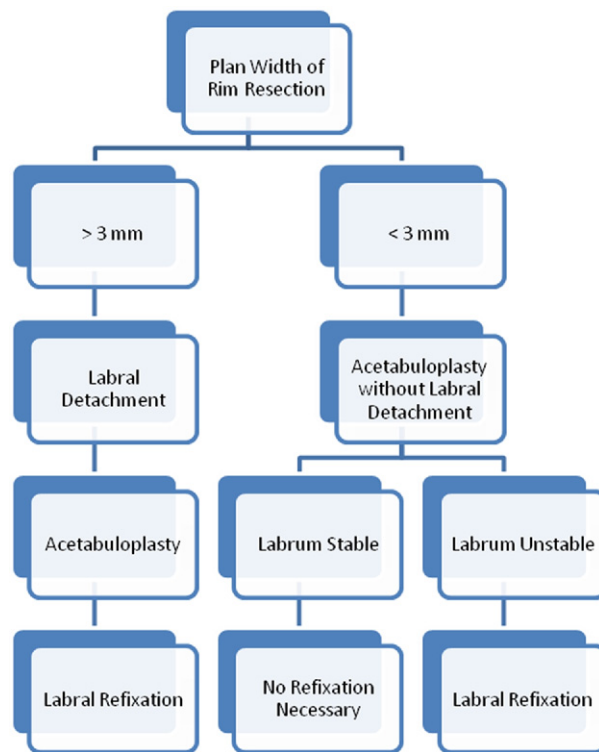


FIGURE 6. Decision algorithm for labral preservation during acetabuloplasty.

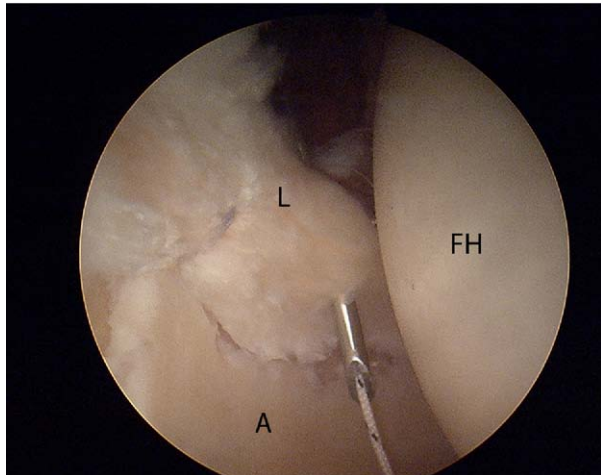


FIGURE 7. Labral base stitch in a right hip viewed from the anterolateral portal. The stitch is passed through the labrum (L) with the Suture Lasso. In this case a No. 2 FiberStick suture (Arthrex) is passed directly through the penetrating instrument, bypassing the need for the Suture Lasso to pass suture. The correct angle of passage of the suture is critical to restoring the anatomy of the labrum. (FH, femoral head; A, acetabulum.)

acetabular volume by 33%.⁴⁰ The labrum consists of an inner, articular-sided layer of fibrocartilage and a larger, outer layer of dense connective tissue organized in circular collagen fibrils. This circular orientation forms a tension ring that is connected at the anterior and posterior horns through the transverse acetabular ligament.⁴¹ It has been shown that under tension, the labrum is actually 10 to 15 times stiffer than the articular cartilage.²⁵

It is thought that when the joint is unloaded, synovial fluid is able to enter the joint to provide nutrition and lubrication.⁴² The labrum, which possesses proprioceptive and nociceptive properties, guides the femoral head into the joint under compressive loading by establishing joint contact at the periphery.^{21,43,44} When peripheral contact is established first, the labrum is able to seal the pressurized synovial fluid in the joint because of its high resistance to radial interstitial flow. The pressurized synovial fluid transmits the load within the cartilage layers to the underlying subchondral bone and slows the expression of fluid

TABLE 3. Selection of Labral Stitch Technique

Thickness of Labrum	Preferred Refixation Technique
>5 mm	LBR with vertical mattress technique
3-5 mm	LBR with single-pass technique
<3 mm	Looped simple stitch technique

TABLE 4. Portal Selection for Anchor Placement

Anchor Placement	Portal
Posterosuperior: 10-12 o'clock	Posterolateral
Anterosuperior: 12-2 o'clock	Anterolateral
Anteroinferior: 2-5 o'clock	Midanterior

NOTE. These clock-face guidelines reflect a right hip in the supine position, where 12 o'clock is superolateral, 3 o'clock is directly anterior, 6 o'clock is inferior at the transverse acetabular ligament, and 9 o'clock is directly posterior.

out of the cartilage matrix, reducing the solid contact stresses on the cartilage.^{22,24,25} The egress of synovial fluid out of the cartilage matrix under compression is known as consolidation. Ferguson et al.²⁴ showed that labral excision in a cadaveric model increased the rate of consolidation by 22%. This rate increased to 48% in joints identified as having a closer fit between the labrum and femoral head. A poroelastic finite element model showed a 40% increase in consolidation rate with labral excision.²³ It was emphasized in this study that the function of the labrum in this capacity is dependent on the contact between the labrum and the femoral head.

Loss of the labral seal has also been shown to destabilize the hip in a cadaveric model.⁴⁵ Femoral head motion increased with both venting of the capsule and creation of a labral tear. Venting of the capsule and subsequent labral injury caused 43% and 60% decreases, respectively, in traction required to create 3 mm of joint distraction. This shows that both the capsular integrity and labral integrity contribute to the vacuum seal of the joint.

The junction of the labral base and the articular surface of the acetabular rim may be important. Findings from revision arthroscopies have shown that the joint capsule can adhere both to the vascularized capsular side of the labrum and to the site of previous acetabuloplasty.^{46,47} Similarly, acetabular labral healing in a sheep model shows 2 types of labral healing, fibrovascular ingrowth from the peripheral joint capsule and direct healing of the labrum to acetabular rim through new bone formation, likely endochondral ossification of fibrous attachment.³⁵ Espinosa et al.¹⁵ emphasized the importance of this bony healing and the need to prepare a bleeding cancellous acetabular rim because of the avascularity of the inner two-thirds of the labrum.

A limitation of this technique is that certain patients may have labra that are too thin to support a labral base stitch. For this reason, the LBR technique is not

recommended if the labrum is thinner than 3 mm. Another concern with this technique, as with many arthroscopic hip procedures, is the necessity for partial capsulotomy. Although LBR preserves the anatomy of the labrum, the function of which has been shown to slow cartilage consolidation, the capsulotomy has also been found to affect cartilage consolidation.²⁴ Whether the capsulotomy and its effects on

TABLE 5. *Technique Pearls for LBR*

Use disposable cannula for working portal.
Use low-profile penetrating device to pass suture through labral base.
Achieve correct passage angle to approximate labral base to acetabular rim.
Place anchors as close to articular surface as possible.
Watch articular surface during anchor placement to avoid articular penetration.

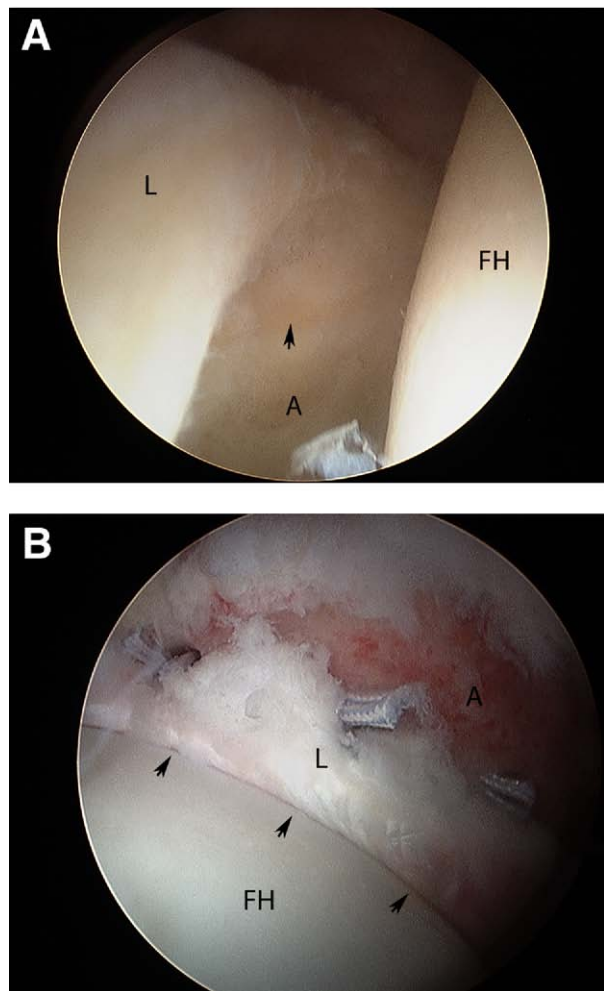


FIGURE 8. (A) Completed LBR in a right hip viewed from the anterolateral portal. This intra-articular view from the central compartment shows the restoration of the normal anatomy of the labrum (L). The nearly seamless transition between the articular cartilage and labrum at the chondrolabral junction (arrow) should be noted. (FH, femoral head; A, acetabulum.) (B) Completed LBR in a left hip viewed through the anterolateral portal from the peripheral compartment after release of traction. It should be noted that the tight contact (arrows) between the labrum (L) and femoral head (FH) has been restored throughout the area of labral repair. The restoration of contact with the femoral head reproduces the labral seal. This allows the labrum to function in maintenance of fluid flow, stability, and suction seal. (A, acetabulum.)

cartilage consolidation have long-term clinical implications is yet to be determined. Furthermore, although short-term follow-up has shown improved outcomes with labral repair versus labral debridement, long-term results are needed to determine whether the natural history of FAI has been affected. Biomechanical and clinical studies will also be essential to determine whether LBR has significant advantages over simple labral repair.

CONCLUSIONS

The 6 goals of labral refixation are directed at restoring the functional anatomy of the labrum. The LBR technique was designed to achieve these goals (Table 5). Splitting and intrasubstance tearing are avoided by use of a small-diameter suture shuttle to pass the labral base stitch through the labrum. Secure reattachment is accomplished with a sufficient number of labral base stitches and anchors, spaced 6 to 8 mm apart. The correct angle of passage of each labral base stitch ensures that the labrum will be fixed to the acetabular rim in an anatomic position, restoring the transitional zone by close approximation of the labral base to the articular cartilage. Triangular cross-sectional geometry of the labrum is preserved by the labral base stitch configuration, which does not bunch or crush the labrum but rather leaves the labral edge free. The LBR avoids eversion of the labrum and strives to reproduce the suction seal by restoring contact with the femoral head. Finally, the refixation is performed with a knotless technique, avoiding any potential abrasion of the articular cartilage by knots.

Restoration of anatomy is a principle that is increasingly considered of paramount importance throughout the field of arthroscopy. The LBR technique follows this principle by providing an anatomic approach to labral repair. This may restore labral function after arthroscopic refixation by allowing the labrum to serve its functions in fluid regulation, stability, load bearing, and maintenance of the suction seal.

REFERENCES

1. Nho S, Ghodadra N, Provencher M, Reiff S, Romeo A. Anatomic reduction and next-generation fixation constructs for arthroscopic repair of crescent, L-shaped, and U-shaped rotator cuff tears. *Arthroscopy* 2009;25:553-559.
2. Lo I, Burkhart S. Double-row arthroscopic rotator cuff repair: Re-establishing the footprint of the rotator cuff. *Arthroscopy* 2003;19:1035-1042.
3. Cole J, ElAttrache N, Anbari A. Arthroscopic rotator cuff repairs: An anatomic and biomechanical rationale for different suture-anchor repair configurations. *Arthroscopy* 2007;23:662-669.
4. Bedi A, Altchek DW. The "footprint" anterior cruciate ligament technique: An anatomic approach to anterior cruciate ligament reconstruction. *Arthroscopy* 2009;25:1128-1138.
5. Cha PS, Brucker PU, West RV, et al. Arthroscopic double-bundle anterior cruciate ligament reconstruction: An anatomic approach. *Arthroscopy* 2005;21:1275.e1-1275.e8. Available online at www.arthroscopyjournal.org.
6. Minagawa H, Itoi E, Konno N. Humeral attachment of the supraspinatus and infraspinatus tendons: An anatomic study. *Arthroscopy* 1998;14:302-306.
7. Ferretti M, Ekdahl M, Shen W, Fu FH. Osseous landmarks of the femoral attachment of the anterior cruciate ligament: An anatomic study. *Arthroscopy* 2007;23:1218-1225.
8. van Eck CF, Romanowski JR, Fu FH. Anatomic single-bundle anterior cruciate ligament reconstruction. *Arthroscopy* 2009;25:943-946.
9. Apreleva M, Ozbaydar M, Fitzgibbons PG, Warner JJP. Rotator cuff tears: The effect of the reconstruction method on three-dimensional repair site area. *Arthroscopy* 2001;18:519-526.
10. Lubowitz J, Poehling G. Watch your footprint: Anatomic ACL reconstruction. *Arthroscopy* 2009;25:1059-1060.
11. Guanache C, Bare A. Arthroscopic treatment of femoroacetabular impingement. *Arthroscopy* 2006;22:95-106.
12. Ganz R, Parvizi J, Beck M, Leunig M, Notzli H, Siebenrock KA. Femoroacetabular impingement: A cause for osteoarthritis of the hip. *Clin Orthop Relat Res* 2003;112-120.
13. Bedi A, Chen N, Robertson W, Kelly B. The management of labral tears and femoroacetabular impingement of the hip in the young, active patient. *Arthroscopy* 2008;24:1135-1145.
14. Byrd T, Jones K. Hip arthroscopy and labral pathology: Prospective analysis with 10-year follow-up. *Arthroscopy* 2009;25:365-368.
15. Espinosa N, Rothenfluh DA, Beck M, Ganz R, Leunig M. Treatment of femoroacetabular impingement: Preliminary results of labral refixation. *J Bone Joint Surg Am* 2006;88:925-935.
16. Philippon MJ, Briggs KK, Yen YM, Kuppersmith DA. Outcomes following hip arthroscopy for femoroacetabular impingement with associated chondrolabral dysfunction: Minimum two-year follow-up. *J Bone Joint Surg Br* 2009;91:16-23.
17. Larson C, Giveans M. Arthroscopic debridement versus refixation of the acetabular labrum associated with femoroacetabular impingement. *Arthroscopy* 2009;25:369-376.
18. Kamath AF, Componovo R, Baldwin K, Israelite CL, Nelson CL. Hip arthroscopy for labral tears: Review of clinical outcomes with 4.8-year mean follow-up. *Am J Sports Med* 2009;37:1721-1727.
19. Byrd JW, Jones KS. Hip arthroscopy in athletes: 10-year follow-up. *Am J Sports Med* 2009;37:2140-2143.
20. Philippon MJ, Yen YM, Briggs KK, Kuppersmith DA, Maxwell RB. Early outcomes after hip arthroscopy for femoroacetabular impingement in the athletic adolescent patient: A preliminary report. *J Pediatr Orthop* 2008;28:705-710.
21. Adeeb S, Sayed Ahmed E, Matyas J, Hart A, Frank B, Shrive N. Congruency effects on load bearing in diarthrodial joints. *Comput Methods Biomech Biomed Eng* 2004;7:147-157.
22. Ferguson SJ, Bryant JT, Ganz R, Ito K. The acetabular labrum seal: A poroelastic finite element model. *Clin Biomech (Bristol, Avon)* 2000;15:463-468.
23. Ferguson SJ, Bryant JT, Ganz R, Ito K. The influence of the acetabular labrum on hip joint cartilage consolidation: A poroelastic finite element model. *J Biomech* 2000;33:953-960.
24. Ferguson SJ, Bryant JT, Ganz R, Ito K. An in vitro investigation of the acetabular labral seal in hip joint mechanics. *J Biomech* 2003;36:171-178.
25. Ferguson SJ, Bryant JT, Ito K. The material properties of the bovine acetabular labrum. *J Orthop Res* 2001;19:887-896.
26. Kelly BT, Weiland DE, Schenker ML, Philippon MJ. Arthroscopic labral repair in the hip: Surgical technique and review of the literature. *Arthroscopy* 2005;21:1496-1504.
27. Murphy KP, Ross AE, Javernick MA, Lehman RA Jr. Repair of the adult acetabular labrum. *Arthroscopy* 2006;22:567.e1-567.e3. Available online at www.arthroscopyjournal.org.
28. Larson C, Giveans M. Arthroscopic treatment of femoroacetabular impingement: Early outcomes evaluation of labral refixation—repair versus debridement. *Arthroscopy* 2008;24:e2-e3 (Abstr). Available online at www.arthroscopyjournal.org.
29. Philippon MJ, Shenker M. A new method of acetabular rim trimming and labral repair. *Clin Sports Med* 2006;25:293-7.
30. Larson CM, Guanache CA, Kelly BT, Clohisy JC, Ranawat AS. Advanced techniques in hip arthroscopy. *Instr Course Lect* 2009;58:423-436.
31. Hernandez JD, McGrath JD. Safe angle for suture anchor insertion during acetabular labral repair. *Arthroscopy* 2008;24:1135-1145.
32. Ganz R, Leunig M. Labral refixation for femoroacetabular impingement. *J Bone Joint Surg Am* 2006;88:925-935.
33. Ross AE, Javernick M, Freedman B, Springer B, Wiend K, Murphy K. Arthroscopic hip labral repair. *Arthroscopy* 2008;22:e30 (Abstr). Available online at www.arthroscopyjournal.org.
34. Philippon MJ, Stubbs AJ, Schenker ML, Maxwell RB, Ganz R, Leunig M. Arthroscopic management of femoroacetabular impingement: Osteoplasty technique and literature review. *Am J Sports Med* 2007;35:1571-1580.
35. Philippon MJ, Arnoczky SP, Torrie A. Arthroscopic repair of the acetabular labrum: A histologic assessment of healing in an ovine model. *Arthroscopy* 2007;23:376-380.
36. Shindle MK, Voos JE, Heyworth BE, et al. Hip arthroscopy in the athletic patient: Current techniques and spectrum of disease. *J Bone Joint Surg Am* 2007;89:29-43 (Suppl 3).
37. Bond J, Knutson Z, Ebert A, Guanache C. The 23-point arthroscopic examination of the hip: Basic setup, portal placement, and surgical technique. *Arthroscopy* 2009;25:416-429.
38. Byrd J. Hip arthroscopy utilizing the supine position. *Arthroscopy* 1994;10:275-280.
39. Ito K, Leunig M, Ganz R. Histopathologic features of the acetabular labrum in femoroacetabular impingement. *Clin Orthop Relat Res* 2004;262-271.
40. Tan V, Seldes RM, Katz MA, Freedhand AM, Klimkiewicz JJ, Fitzgerald RH Jr. Contribution of acetabular labrum to articulating surface area and femoral head coverage in adult hip joints: An anatomic study in cadavera. *Am J Orthop* 2001;30:809-812.
41. Petersen W, Petersen F, Tillmann B. Structure and vascularization of the acetabular labrum with regard to the pathogenesis and healing of labral lesions. *Arch Orthop Trauma Surg* 2003;123:283-288.
42. Greenwald AS, O'Connor JJ. The transmission of load through the human hip joint. *J Biomech* 1971;4:504-528.
43. Kim YT, Azuma H. The nerve endings of the acetabular labrum. *Clin Orthop Relat Res* 1995:176-181.

44. Shirai C, Ohtori S, Kishida S, Harada Y, Moriya H. The pattern of distribution of PGP 9.5 and TNF-alpha immunoreactive sensory nerve fibers in the labrum and synovium of the human hip joint. *Neurosci Lett* 2009;450:18-22.
45. Crawford M, Dy C, Noble P. The biomechanics of the hip labrum and the stability of the hip. *Clin Orthop Relat Res* 2007;465:16-22.
46. Krueger A, Leunig M, Siebenrock KA, Beck M. Hip arthroscopy after previous surgical hip dislocation for femoroacetabular impingement. *Arthroscopy* 2007;23:1285-1289.e1. Available online at www.arthroscopyjournal.org.
47. Philippon MJ, Schenker ML, Briggs KK, Kuppersmith DA, Maxwell RB, Stubbs AJ. Revision hip arthroscopy. *Am J Sports Med* 2007;35:1918-1921.